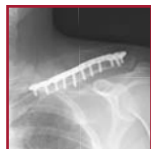

ACUMED®

Innovative Solutions



Locking Clavicle Plating System

Locking Clavicle Plating System

CONTENTS

Introducing the System	2
System Plate Features	3
Approach-specific Plates	4
Low and Narrow-profile Superior Midshaft Plates	
Anterior Medial and Lateral Plates	
Locking Distal Clavicle Plates	
Comprehensive Plate Design	8
Improved Healing Capacity	9
Precise Screw Placement	10
Biomechanical Studies	11
Surgical Techniques	
Locking Midshaft Clavicle Plate Surgical Technique	12
Locking Anterior Clavicle Plate Surgical Technique	16
Locking Distal Clavicle Plate Surgical Technique	20
Additional Shoulder Solutions	24
Ordering Information	25
Notes	26

Since its introduction as the orthopaedic industry's first anatomic resource for clavicle fixation, surgeons have utilized the versatility of the Acumed Locking Clavicle Plate System to treat simple and complex fractures, malunions and nonunions located from the medial-third to distal-third of the clavicle.

Designed in conjunction with William B. Geissler, M.D., Acumed's objective is to provide a comprehensive solution for repairing clavicular fractures. This is in recognition that traditional hardware including pinning, reconstruction and dynamic compression plating have historically provided less than desirable results including soft tissue irritation and/or failure prior to union, requiring a second surgical procedure.¹

The Locking Clavicle Plating System is distinct and recognized for offering a novel array of low and narrow-profile plate solutions, precontoured to match the natural S-shape of the clavicle. This achievement affords surgeons the opportunity to choose the most appropriate option for the patient, reduces OR time spent contouring a plate and minimizes soft tissue irritation for the patient; all of which reduce the need for additional surgical procedures.

Indication-specific Plate Designs Include:

Locking Superior Midshaft Plates: Comprised of 16 plates, this system offers the most extensive array of superior plate options available for midshaft clavicle fractures including six narrow-profile plates that enhance a surgeon's ability to treat patients with a small bone structure.

Locking Anterior Plates: For complex oblique fracture patterns as well as for surgeons who desire an anterior approach which is perceived to minimize risk, increase screw purchase in bone and reduce hardware prominence.

Locking Distal Plates: Treat complex lateral-third clavicle fractures through plate and screw positioning that precisely targets distal fragments and provides secure, stable fixation for multiple fracture patterns, especially when disruption of the coracoclavicular (CC) ligaments is evident.



Indications: acute, displaced, comminuted, midshaft, and isolated distal clavicle fractures, including malunions, nonunions and osteotomies.

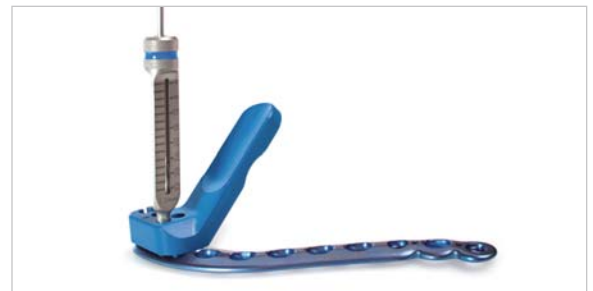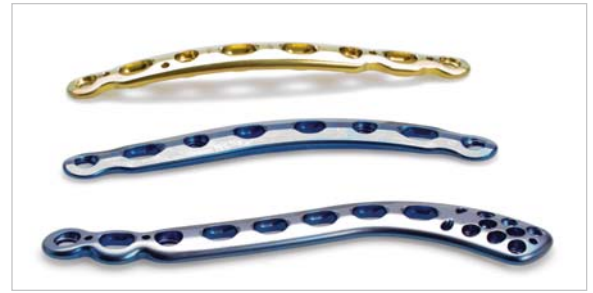Locking Clavicle System Plate Features

Precontoured Anatomic Plate Design assists in restoring the original geometry of the patient's anatomy with little or no bending, which saves valuable OR time. Acumed's comprehensive system of plates replicate the anatomical contours of the clavicle and act as templates when reconstructing a malunion, nonunion or a highly comminuted fracture to maximize support and accurately reduce the fracture.

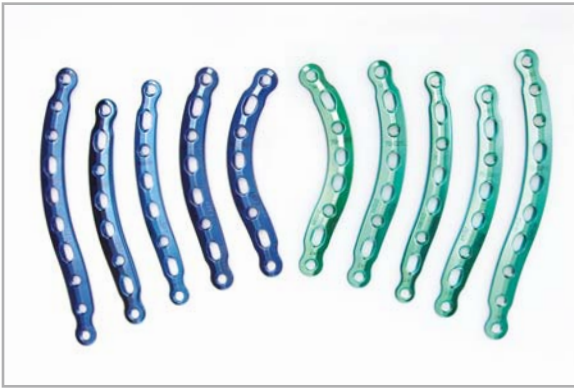
Approach-specific Plates provide a complete clavicle plating solution for the midshaft superior aspect, anterior medial and lateral regions as well as plates for lateral-third applications. This empowers the surgeon to choose the best available option for treating the characteristics of the fracture pattern or select plates based upon their preferred surgical approach (superior or anterior) when treating midshaft fractures.

Improved Healing Capacity resulting from several key features: machined from a premium grade titanium alloy, the plates perform with a modulus of elasticity that closely replicates bone and reduces the propensity for stress shielding; a limited contact design eases compression of the periosteum to improve blood supply to the healing zone; tapered plate ends lessen the possibility of bone refracture above or below the plate due to excess stress concentrations. Acumed's Distal Clavicle Plates include suture holes for adjunct procedures that further increase stability.

Precise Screw and Plate Placement facilitates maximum bone purchase, a critical factor in increasing pull-out resistance. Angled screw holes in the medial and lateral holes of the superior midshaft plate allow for drilling and screw insertion without the patient's head becoming an obstacle. Acumed's Distal Clavicle Plates utilize K-wire and suture holes to verify plate and screw placement allowing the surgeon to address the most lateral fracture patterns. Targeting guides ensure the fixed angle distal screws are properly inserted and seated flush with the plates surface.



Locking Clavicle System Approach-specific Plates



Low-profile Superior Midshaft: Acumed offers an extensive selection of locking plates for superior midshaft applications. Placed on the tension side of the clavicle, studies have found superior plating to be a biomechanically stronger construct.² Narrow-profile plates specifically treat patients with small bone structures and reduce their risk of soft tissue irritation. This comprehensive 16-plate selection provides a range of plate lengths, widths, and various thicknesses to stabilize the clavicle at the surgeon's discretion regarding patients activity level and body habitus.

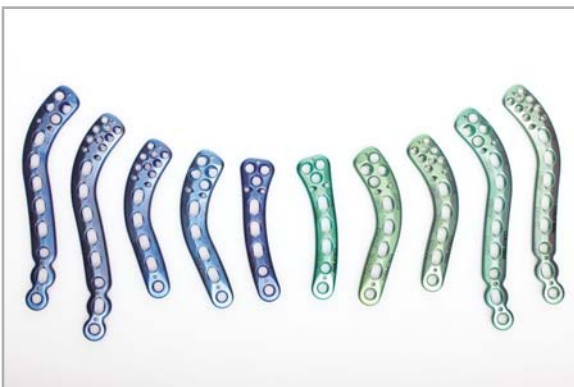

Narrow-profile Superior Midshaft: For patients with a small bone structure, Acumed offers six narrow-profile plates. This set compliments Acumed's assortment of low-profile superior midshaft plates to offer the most extensive array of superior plate options available for reconstructing comminuted midshaft clavicle fractures, malunions and nonunions.

Narrow-profile plates should only be used for patients with a small bone structure or sedentary lifestyle.



Anterior Medial and Lateral: Certain fracture patterns, such as an elongated oblique fracture, may require an anterior approach, or a surgeon may prefer an anterior method when plating a clavicle fracture. Cited advantages to anterior plates include: increased bone stock for maximized screw purchase, reduced soft tissue irritation and a safer approach, as instrumentation is directed away from vital subclavian vessels.

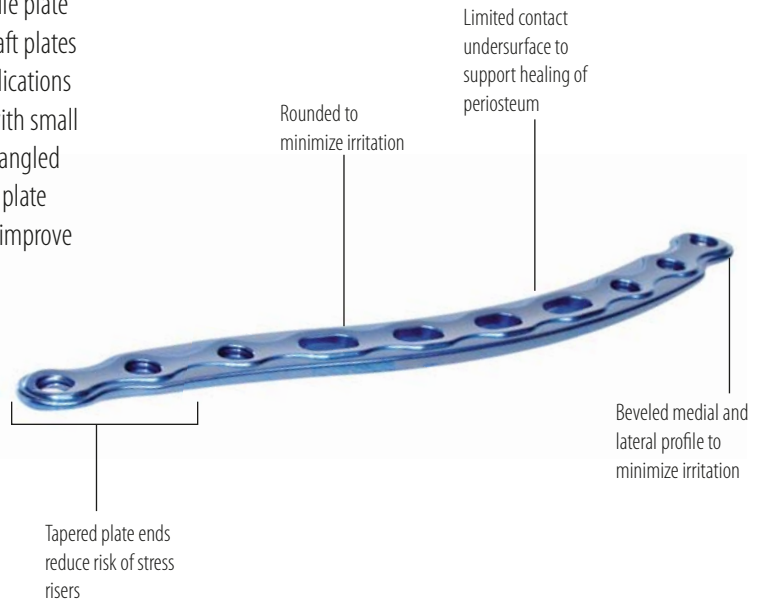
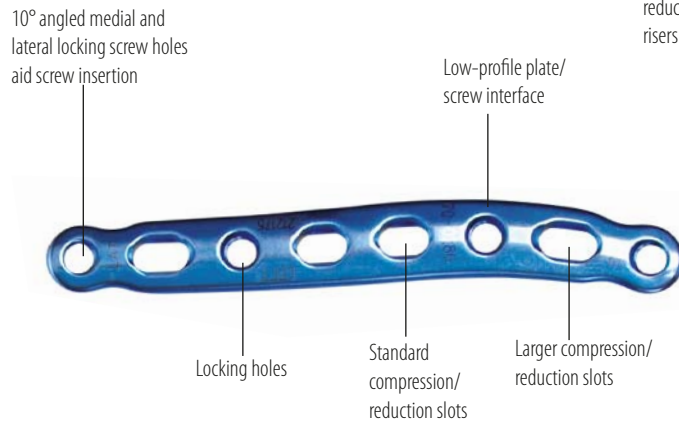


Superior Distal: Due to the ligamentous and musculature deforming forces that act upon the lateral clavicle region, distal clavicle fractures are recognized as having distinct patterns and a corresponding high nonunion rate. With 3, 4 and 8-hole distal options, Acumed's Locking Distal Plates offer a range of solutions with key features such as K-wire and suture holes for optimum plate and screw placement.

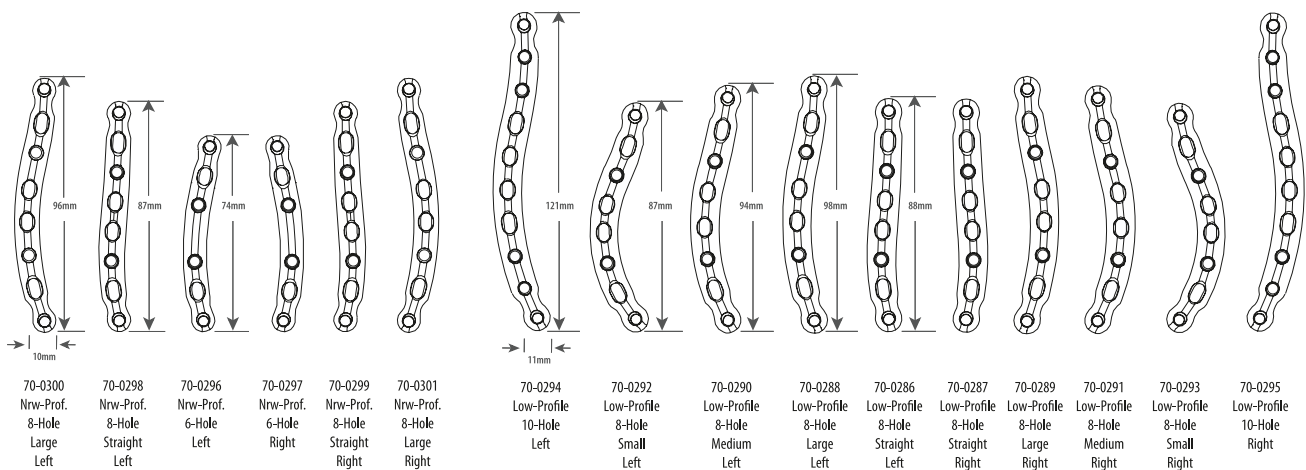
Low and Narrow-profile Superior Midshaft Plates

Acumed's Superior Midshaft Plate System offers the most extensive array of superior plate options available for midshaft clavicle fractures, malunions and nonunions with 16 precontoured low-profile and narrow-profile plate options. Surgeons can choose from 10 low-profile superior midshaft plates in five lengths (left and right-specific) to address central-third applications — and from six narrow-profile plates to accommodate patients with small bone structure. With a limited contact design, tapered plate ends, angled medial and lateral screw holes and screws which sit flush with the plate surface, each implant is designed to increase healing capacity and improve the surgical procedure.

Low-Profile 8-Hole Straight and Low-Profile 10-Hole Locking Superior Midshaft Plates are shown.




- All plates have a combination of compression slots and locking holes for maximum fixation
- Titanium construct reduces potential cold welding between plates and screws
- Highly polished surface to prevent soft tissue adherence
- Premium grade titanium alloy for improved strength and low-profile plate geometry
- Color-coded green and blue for easy plate identification
- Laser marked for orientation reference



Anterior Medial and Lateral Plates

Acumed's Locking Anterior Plate System offers multiple options to address fracture patterns and accommodate preferred surgical approaches — and complements the superior midshaft plates to provide a complete clavicle plating solution. Manufactured from a superior grade titanium to maximize biomechanical strength, our anterior plates offer clear advantages for treating clavicle fractures: increased bone stock for maximized screw purchase, reduced soft tissue irritation and a safer approach as instrumentation is directed away from vital subclavian vessels.

Tapered medial and lateral plate ends to minimize irritation and reduce stress concentrations



Limited contact design reduces constriction of the blood supply to the periosteum

Low-profile screw/plate interface

Beveled superior and inferior profiles minimize irritation and reduce stress concentrations



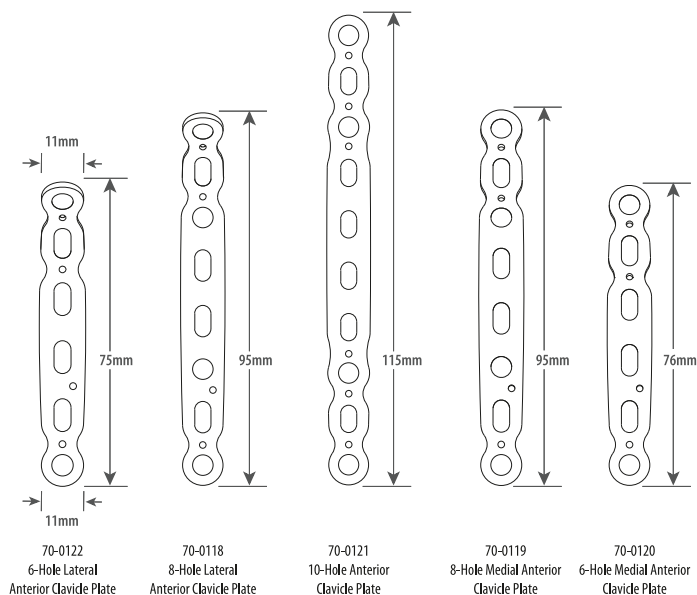
.062" K-wire holes for provisional stability

Locking screw holes

Standard compression/reduction slots

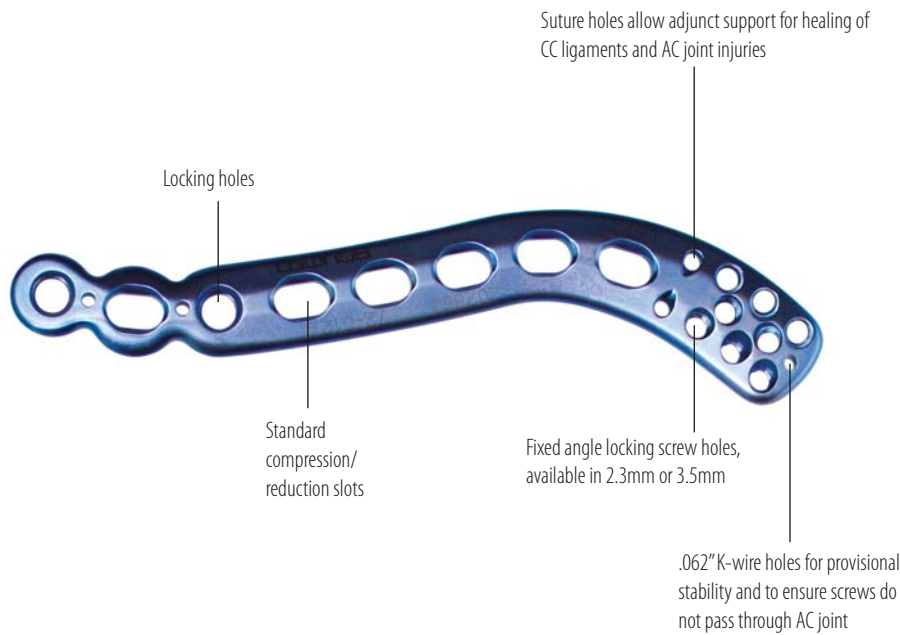
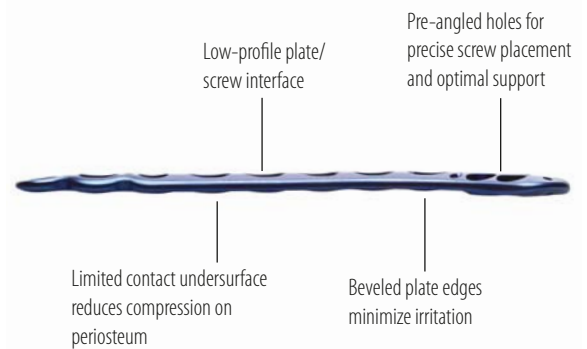
6-Hole Medial Anterior Locking Clavicle and 10-Hole Anterior Locking Clavicle plates shown

- All plates have a combination of compression slots and locking holes for maximum fixation
- Titanium construct reduces potential cold welding between plates and screws
- Highly polished surface to prevent soft tissue adherence
- Premium grade titanium alloy for improved strength and low-profile plate geometry
- Color-coded for easy plate identification
- Laser marked for orientation reference



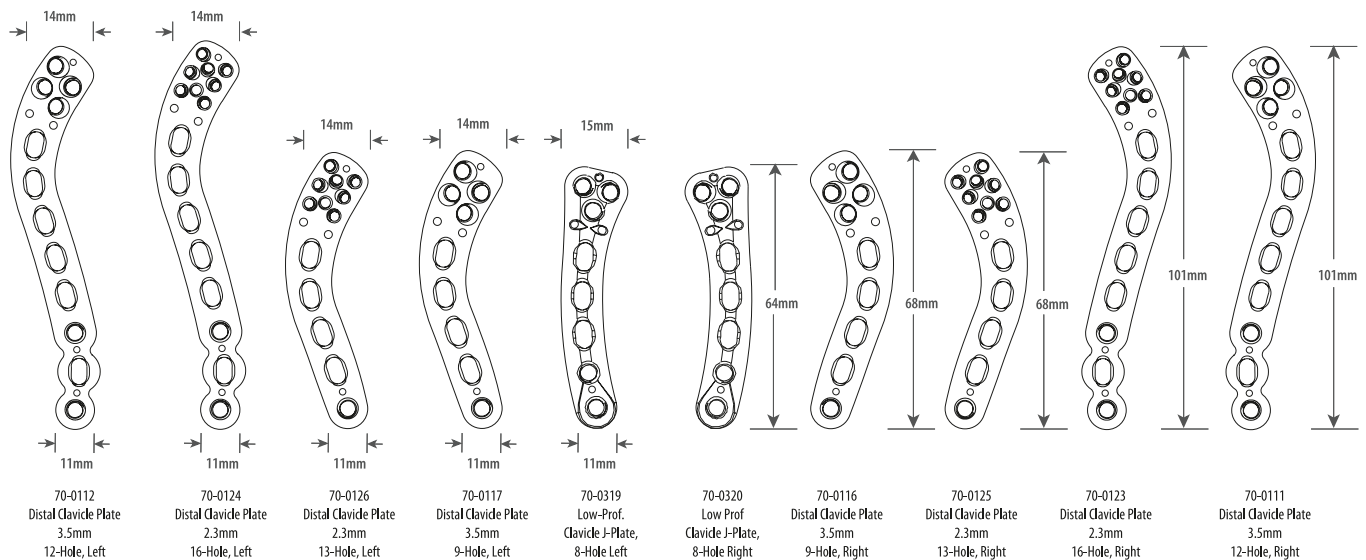
Locking Distal Clavicle Plates

Addressing the distinct challenges presented by lateral-third clavicle fractures, Acumed's Locking Distal Clavicle Plates feature multiple screw configurations to maximize bone purchase and increase plate stability. Available in multiple lengths and screw configurations, this plate selection provides enhanced fracture fixation and stability for lateral-third clavicle fractures — especially where there is disruption to coracoclavicular (CC) ligaments.

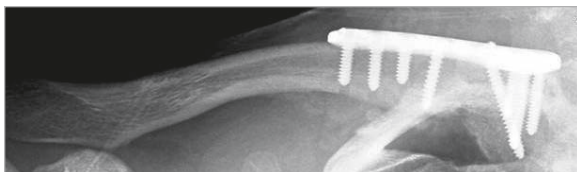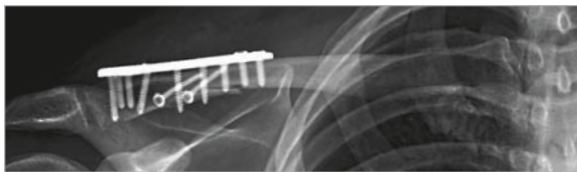
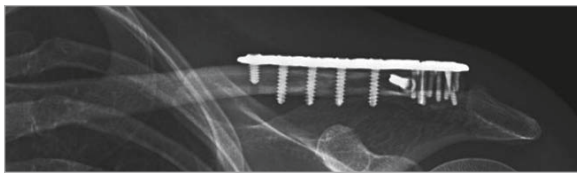
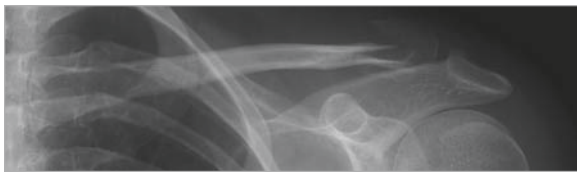
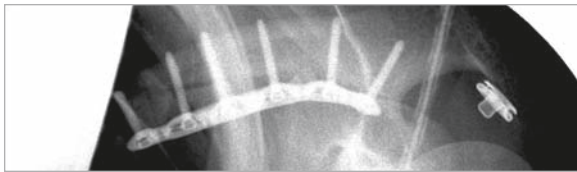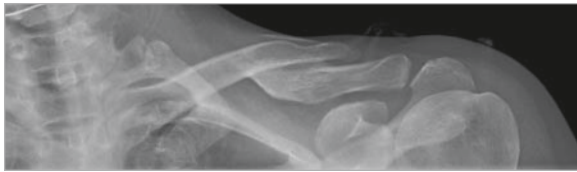


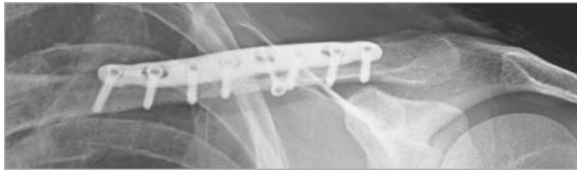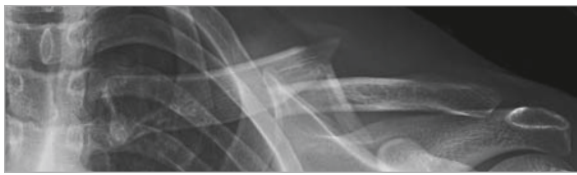- All plates have a combination of compression slots and locking holes for maximum fixation
- Titanium construct reduces potential cold welding between plates and screws
- Highly polished surface to prevent soft tissue adherence
- Premium grade titanium alloy for improved strength and low-profile plate geometry
- Color-coded blue and green for easy plate identification
- Laser marked for orientation reference

16-Hole Distal Locking Clavicle Plate and 12-Hole Locking Clavicle Plates are shown.



Comprehensive Plate Design



Aided by extensive cadaveric research and clinical experience, Acumed's Locking Clavicle System is a comprehensive collection of precontoured, approach-specific plates designed to replicate the anatomic contour of the clavicle. Comprised of 31 plates across three distinct surgical designs: or - superior midshaft, superior distal, anterior medial and lateral - Acumed provides a complete clavicle plating solution with multiple options for different fracture patterns.

These options are significant as illustrated by two recent studies analyzing clavicle morphology. Results from one study showed that the clavicle demonstrated both gender as well as side specific geometric morphology with the possibility of at least five morphological groups (Table 1). Further, while findings indicate that men generally have longer clavicles that are thicker and wider at their midpoints, there is no difference in the width of any implants across their entire lengths.³ Another study examining the distal region of 20 clavicles cited large variations in the morphology, including two specific types – polygonal and oval.⁴

To address the multitude of anatomies and fracture patterns, Acumed provides the following solutions:

Superior Midshaft; 16 low and narrow-profile plate curvatures including six plates to specifically treat patients with small bone structures.

Anterior Medial and Lateral; five plate curvatures in 6, 8 and 10-hole lengths for unique fracture patterns such as an elongated oblique fracture.

Superior Distal; three design styles 3, 4 and 8-hole options to address the challenging fracture patterns and eliminate the corresponding high nonunion rate associated with distal clavicle fractures.

The versatility of Acumed's J-plate offers the advantage of addressing not only distal fractures, but challenging medial clavicle fractures.

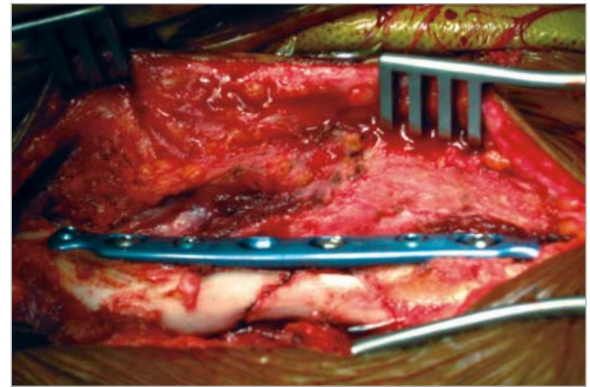
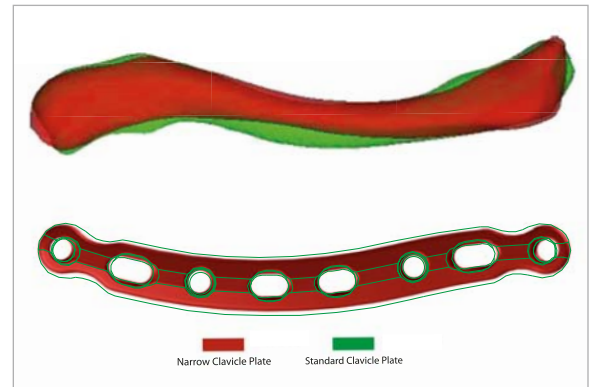
	Superior View	Dorsal View
Group 1 Composed of 4 Male Clavicles		
Group 2 Composed of 1 Male Clavicle		
Group 3 Composed of 1 Male Clavicle		
Group 4 Composed of 6 female Clavicles		
Group 5 Composed of 9 female Clavicles		

Table 1. Zubin's Five Morphological Clavicle Groups



Improved Healing Capacity

Acumed's Locking Clavicle Plates feature improved plate composition, low and narrow-profile designs, limited contact undersurface, tapered plate ends, angled screw holes and K-wire and suture holes. The plates improve healing capacity, ease the surgical procedure and reduce the potential for hardware removal. Each locking clavicle plate is machined from a single block of high grade titanium alloy for maximum strength. Titanium's modulus of elasticity is a significant benefit as it is more similar to natural bone than rigid stainless steel, which has a higher propensity for stress shielding.

- Low-profile and narrow-profile plate constructs minimize postoperative soft tissue irritation and patient discomfort
- Narrow-profile plate options allow surgeons to better address contrasting anatomies such as those between genders
- Limited contact design reduces periosteum compression and improves blood supply to the healing zone
- Locking and nonlocking screws sit flush with the plate, eliminating soft tissue irritation
- Tapered plate ends reduce the risk of refracture due to stress risers at either end of the plate
- 10° screw angles for the outermost medial and lateral locking holes allow surgeons to drill and insert screws without the patient's head becoming an obstacle, even if the plate is rotated 180°
- With disruption of coracoclavicular (CC) ligaments, suture holes allow adjunct techniques to provide increased stability and give the ligaments time to heal
- K-wire holes allow precise placement and verification that the AC joint is not violated



Precise Screw Placement



- Color-coded left and right drill guide blocks provided
- Calibrated drill and drill guide
- Drilling, measuring and screw insertion through attached drill guide block
- Radiolucent drill guide block for rapid and accurate insertion of screws

Precise screw and plate placement designed into Acumed's Locking Clavicle Plates maximizes bone purchase and increases pull-out resistance, especially when countering axial loads in lateral-third fractures. Acumed's Midshaft Plates incorporate angled medial and lateral screw holes to ease the surgical procedure by allowing for drilling and screw insertion without the patient's head becoming an obstacle.

- Acumed's distal plates can be placed far more distal than competitor plates to address the most lateral of fracture patterns
- Targeting guides ensure the fixed-angle distal screws are properly inserted and seated flush with the plate surface

- Multiple distal screw configurations offer improved fixation options for fracture patterns and preferred surgical technique
- Combined with proximal shaft screws, the plate provides maximum fixation to promote fracture union
- Fixed angles to avoid joint penetration
- K-wire holes to assist with temporary fixation and verification of optimal plate position

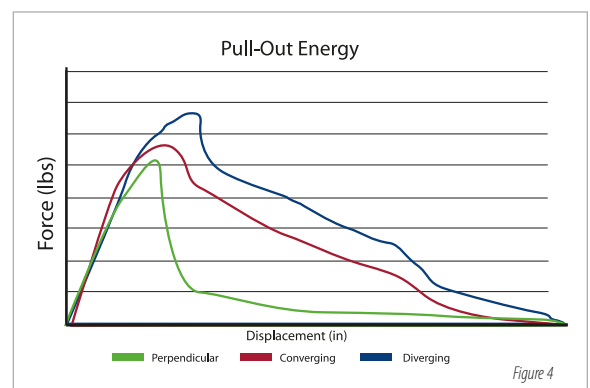
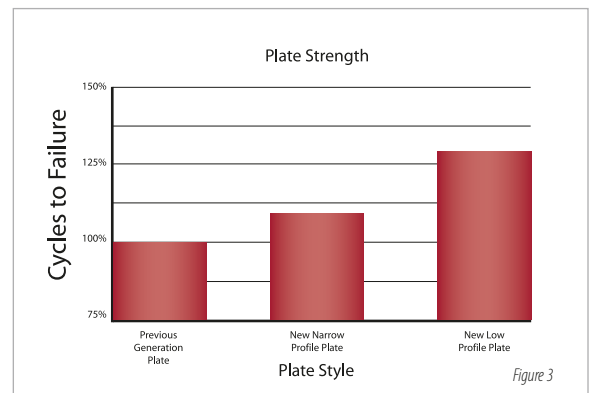
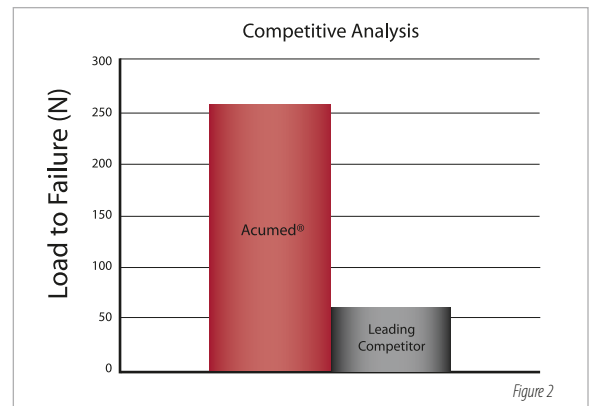
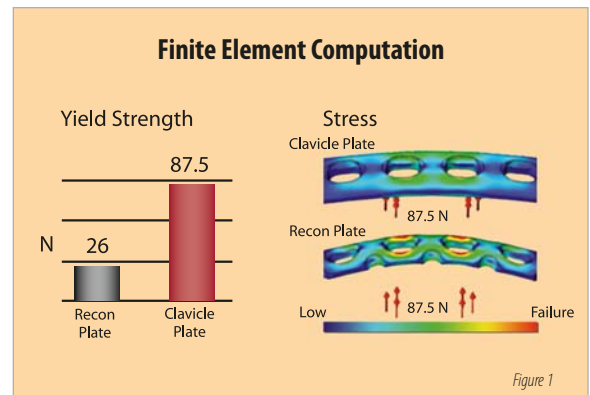


Strength and plate composition are recognized and respected components of Acumed's Locking Clavicle System. In-house analysis of our initial system showed that when subjected to equal force, a 3.5mm stainless steel reconstruction plate broke in multiple locations while Acumed's titanium plate suffered no permanent deformation (Figure 1).⁵ Findings reinforced in a published study evaluating in-vitro biomechanical properties of Acumed's precontoured titanium clavicle plate to a competitor's 3.5mm limited contact dynamic compression (LCDC) plate. Results showed the plates did not differ in axial tension, axial compression, torsional tension or torsional compression after plating.⁶ The authors noted that "The precontoured clavicle plate may afford several potential advantages. It has the anatomic shape of the natural clavicle and, with available right and left clavicle fittings, may decrease operative time. With a lower profile and round end, compared to the 3.5mm LCDC plate, greater cosmesis and patient tolerance of the plate are possible. The lower modules of elasticity of titanium compared to stainless steel may lead to less stress shielding."⁷

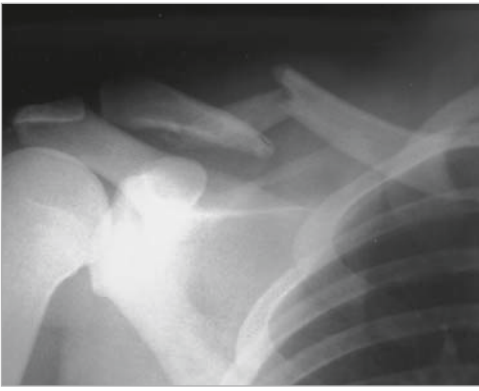
While impressive, Acumed recognized that advances in medical manufacturing may enhance the ability to engineer features that further increase plate strength. Acumed stringently tested the spectrum of medically implantable grade titanium to identify the highest grade for manufacturing and thereby improve patient outcomes while retaining the significant advantages of titanium's low modulus of elasticity.

Biomechanical tests conducted by an independent university laboratory analyzed several plate constructs and applications to the bone. One such test compared the strength of Acumed's 8-hole titanium Locking Anterior Clavicle Plate to a competitor's 316L stainless steel reconstruction plate. Results showed Acumed's Anterior Clavicle Plate withstood 14-times more cycles to failure in fatigue than the competitor's reconstruction plate (Figure 2).⁸ In a plate comparison analyzing the Acumed clavicle plates manufactured from the previous titanium construct to that of the new titanium alloy composition, the lab proved out an increase in plate strength for both low and narrow-profile plate designs (Figure 3). This strength increase allows for a 13-percent reduction in plate geometry compared to Acumed's previous line of locking clavicle plates. This further reduces soft tissue irritation, the need for hardware removal and perhaps most importantly, a narrow-profile plate design to accommodate patients with small bone structure.

Scientific literature shows a Locking Compression Plate (LCP) applied to the superior aspect of the clavicle is susceptible to failure when the screws are loaded in a purely axial direction. Particularly in the lateral clavicle, where the weight of the arm can pull downward on the clavicle and cause it to sag away from the plate.⁹ Acumed addressed this challenge in the design of our Locking Distal Clavicle Plates by providing options with a series of diverging and converging 2.3mm or 3.5mm screws for significantly increased resistance to axial pull-out forces as compared to 3.5mm screws placed perpendicular to the plate. A series of in-house mechanical tests showed diverging/converging screws positively impact pull-out force (Figure 4).¹⁰



Locking Midshaft Clavicle Plate

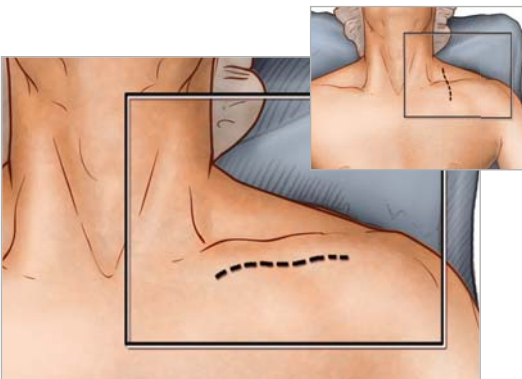


1 Preoperative Planning and Patient Positioning

After completion of a thorough radiographic evaluation, the patient is placed in a beach chair position with the head rotated and tilted 5° to 10° away from the operative side. A bolster is placed between the shoulder blades and head allowing the injured shoulder girdle to retract posteriorly. This will facilitate reduction by bringing the clavicle anterior to restore length and improve exposure. The patient's involved upper extremity is prepped and draped in a sterile fashion allowing the arm to be manipulated to help further reduce the fracture if required.

Radiographic options for midshaft clavicle fractures:

Radiographic evaluation begins with an anteroposterior (AP) view to evaluate the acromioclavicular (AC), coracoclavicular (CC) and sternoclavicular (SC) joints. If thoracic structures obstruct the image, a 20° to 60° cephalad-tilted view may be utilized. For displaced fracture fragments, especially in the event of a vertically oriented butterfly fragment, a 45° AP oblique view may be helpful. If subluxation or dislocation of the medial clavicle or the SC joint is suspected, a 40° cephalic tilt view (serendipity view) of the SC joint or CT Scan is recommended.¹¹ If the decision on operative treatment is influenced by shortening of the clavicle, a Posterior-anterior (PA) 15° caudal x-ray is suggested to assess the difference compared to the non-injured side.¹²

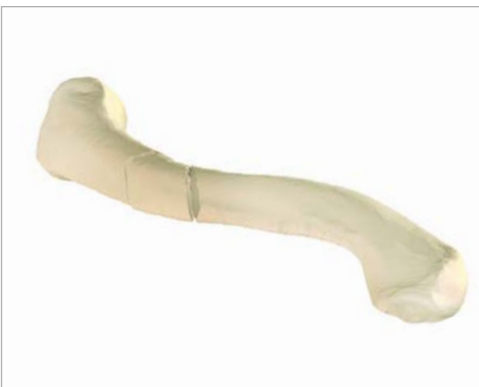

2 Exposure

Surgeons may choose one of two incisions: Option one, a 3cm to 5cm transverse (medial to lateral) infraclavicular incision is made parallel to the long axis of the clavicle so that the scar does not lie over the plate. This approach provides convenient, unlimited access to the entire length of the bone. Option two, an incision along Langer's Lines running perpendicular to the long axis provides better cosmetic results and less damage to the supraclavicular cutaneous nerves.

The subcutaneous fat is incised together with any fibers of the platysma. Identifying and protecting branches of the supraclavicular nerves preserves cutaneous sensation inferior to the incision. The pectoralis fascia is divided in line with the incision and elevated with electrocautery to create thick flaps that can be closed over the plate at the end of the procedure.

Tip: It is important to keep soft tissue attachments to the butterfly fragments in an attempt to maintain vascularity.



3 Plate Selection

Reduce the fracture by placing two reduction forceps (PL-CL04) on the medial and distal fragments (medial fragment is usually proximal in relation to the distal fragment). Distract, elevate and rotate the distal fragment to obtain reduction. The appropriately sized left or right Midshaft Clavicle Plate is selected from the different lengths and curvatures in the system. Place the two middle compression slots over the fracture, ideally leaving three locking and/or nonlocking holes both medial and distal to the fracture fragments. The plate may be slid medially or laterally for the most ideal location. In cases of nonunion or malunion, the curve of the plate may assist in anatomic reduction of the clavicle, reducing strain on the SC and AC joints.

Tips: Prior to placement of the plate, lag screw fixation across the major fracture fragments may be performed for neutralization or axial compression. To reduce and fix the bigger intermediate fragments to one or both main fragments before applying the plate, drill the near cortex with the 3.5mm drill (MS-DC35). Insert the 3.5mm Narrow Drill Guide (PL-2196) and drill the far cortex using a 2.8mm drill (MS-DC28). It is important to preserve the soft tissue attachments.

A countersink (PL-2080) is available to facilitate placement of interfragmentary screws.

Usually the larger plates are ideal for most males, medium plates for smaller males and most females and the narrow-profile plates for the smallest patients.

4 Plate Placement

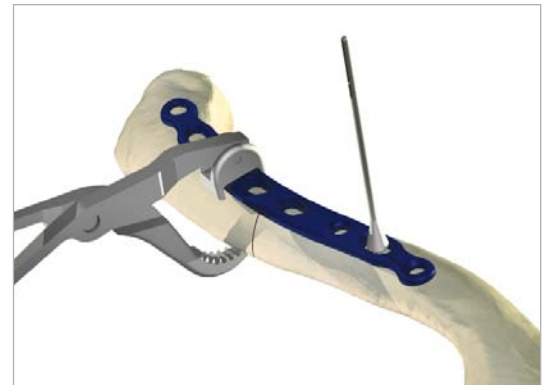

Once the plate's ideal positioning has been selected, it is provisionally stabilized to the clavicle with plate tacks (PL-PTACK) or plate clamps (80-0223). Ideally the plate should be applied in compression mode using the 2.8mm offset drill guide (PL-2095) to reduce the risk of delayed union or nonunion. The plate may be applied to one of the major fracture fragments and used as a tool to reduce other major fragments to this bone-plate construct. Take care to ensure that the intervening fragments are not stripped. Preservation of soft tissue attachments helps ensure that the length and rotation of the clavicle are correct.

Tips: For a more anatomical fit on fractures that are more medial or lateral than the central-third, the plate may be rotated 180° or a plate of the opposite dexterity may be used if the patient's anatomy requires a different curvature than that provided with the correct-sided plate.

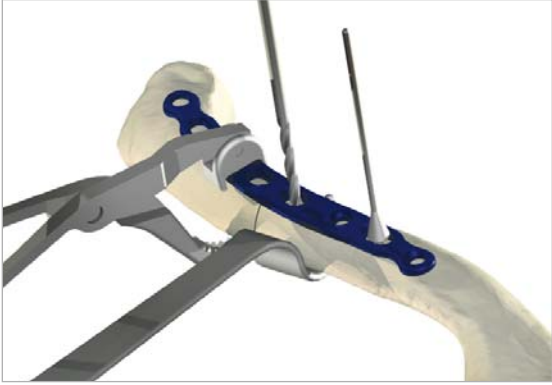
Plate benders (PL-2045) are available in the event further contouring is required.

Tips: The plate may be rotated 180° for a more anatomical fit.

Avoid using the PL-CL04 plate clamp in securing the plate to the bone as the serrated jaws will cause scarring to the plate surface.



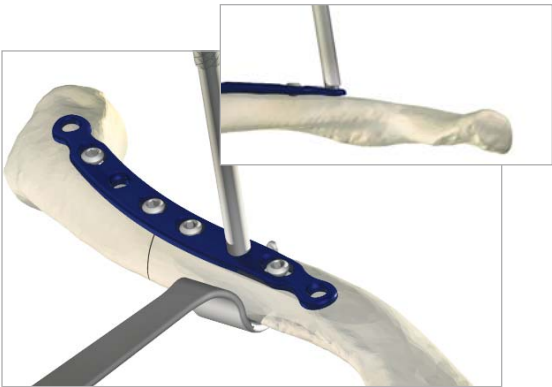
Locking Midshaft Clavicle Plate



5 Nonlocking Screw Insertion

Nonlocking screws may be placed either unicortical or bicortical. If bicortical screws are used, it is important to not over-penetrate the inferior cortex and potentially risk neurovascular injury. The clavicle retractor (PL-CL03) or other means of protection should be placed under the inferior surface of the clavicle to protect the neurovascular structures from over-penetration of the drill bit. For early stability, the first two screws placed should be medial and lateral to the fracture site. Although 3.5mm cortical screws (CO-3XX0) are recommended, optional 2.7mm cortical (CO-27XX) and 4.0mm cancellous (CA-4XX0) screws are available. Assemble the driver handle (MS-3200 or MS-1210) to the driver tip (HPC-0025 or HT-2502). Using the appropriate drill size (MS-DC28) and the offset drill guide (PL-2095), drill, measure for depth (MS-9022) and place the screws into the slots with the assembled driver. Once two screws are installed, the plate tacks or bone clamps holding the plate to the clavicle may be removed.

Tip: Replace drill if it comes in contact with clavicle retractor.



6 Locking Screw Insertion

Using the locking drill guide (MS-LDG35) and the 2.8mm drill (MS-DC28), place the 3.5mm locking screws (COL-3XX0) into the threaded holes so that there are at least three screws (if possible) on each side of the fracture.

Tips: The outer most medial and lateral holes are angled 10° and the locking drill guides must be inserted to account for these angles.

Tapping (MS-LTT35 or MS-LTT27) is recommended for patients with dense bone. The drill guide must be removed prior to tapping.

If the position of the patient's head is an obstacle when attempting to access the medial screw hole, the flexible hex driver (80-0302) may be utilized to facilitate screw insertion.

Depending on the degree of comminution, demineralized bone matrix, iliac crest autograft, or allograft bone chips may be used to fill areas devoid of bone.¹³ In hypertrophic nonunions, callus from the nonunion site may be sufficient to provide graft material.

7 Final Plate and Screw Position

An intraoperative radiograph is recommended to check the position of the screws and the final reduction of the fracture. If the surgeon feels the bone quality of the lateral fragment is poor, sutures may be passed from medial to lateral around the coracoid and the plate to take stress off of the lateral fixation. After radiographic evaluation and thorough irrigation, the clavipectoral fascia is closed over the clavicle and the plate, followed by closure of the subcutaneous tissue and musculature in separate layers. Finally, close the skin by using interrupted absorbable sutures with a subcuticular stitch and dress the wound.

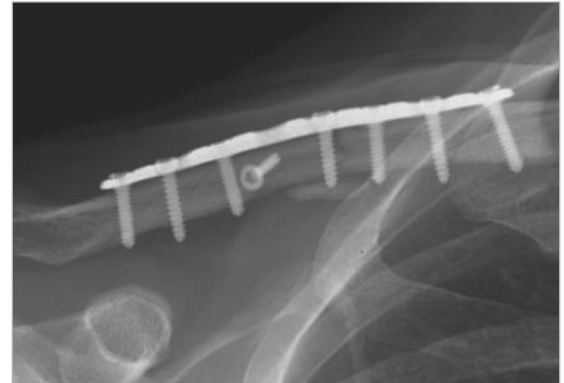
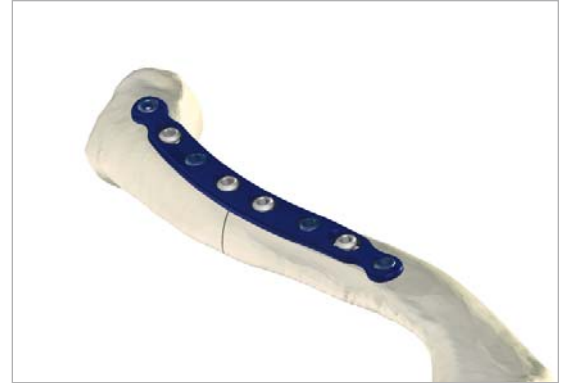Post-op Protocol

For the first four weeks, the patient is placed in either an arm sling or an abduction pillow to bring the arm up and the clavicle down, unloading the AC joint.¹⁴ Passive range of motion exercises are initiated during the first four weeks. Exercises may include pendulum, Codman, isometric bicep, and elbow and wrist motion. It should be emphasized to patients that they must avoid any activity involving heavy lifting, pushing or pulling. Depending on the amount of comminution and the stability of fixation, active assisted exercise is started from four to six weeks, and active strengthening is initiated at six to eight weeks postoperatively, once healing is seen radiographically. A full return to activities is permitted once healing has occurred.

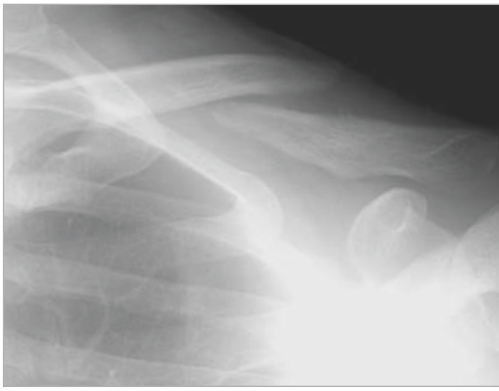Tip: Due to risk of refracture, implant removal is generally not recommended before two years after ORIF.

Contraindications

Preoperative planning and patient selection are crucial. Patients at high risk for multiple falls, alcohol abuse, or non-compliance may have early mechanical failure of the fixation and are not candidates for this procedure. Additional contraindications include: active infection in the operative area; prior soft tissue irradiation in the operative area; burns over the clavicular area; debilitating medical conditions. Patients who are unable or unwilling to participate in a postoperative rehabilitation program are not candidates for surgical intervention.¹⁵



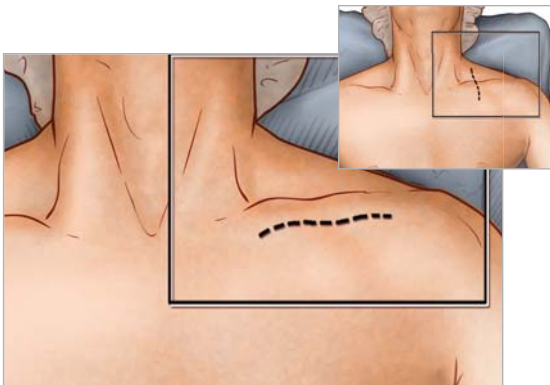
Locking Anterior Clavicle Plate



1 Preoperative Planning and Patient Positioning

After completion of a thorough radiographic evaluation, the patient is placed in a beach chair position with the head rotated and tilted 5° to 10° away from the operative side. A bolster is placed between the shoulder blades and head allowing the injured shoulder girdle to retract posteriorly. This will facilitate reduction by bringing the clavicle anterior to restore length and improve exposure. The patient's involved upper extremity is prepped and draped in a sterile fashion allowing the arm to be manipulated to help further reduce the fracture if required.

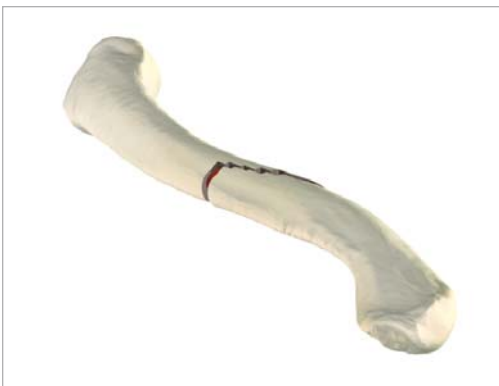Tip: Radiographic evaluation begins with an anteroposterior (AP) view to evaluate the acromioclavicular (AC), coracoclavicular (CC) and sternoclavicular (SC) joints. If thoracic structures obstruct the image, a 20° to 60° cephalad-tilted view may be utilized. For displaced fracture fragments, especially in the event of a vertically oriented butterfly fragment, a 45° AP oblique view may be helpful. If subluxation or dislocation of the medial clavicle or the SC joint is suspected, a 40° cephalic tilt view (serendipity view) of the SC joint or CT Scan is recommended.¹⁶ If the decision on operative treatment is influenced by shortening of the clavicle, a Posterior-anterior (PA) 15° caudal x-ray is suggested to assess the difference compared to the non-injured side.¹⁷



2 Exposure

Surgeons may choose one of two incisions: Option one, a 3cm to 5cm transverse (medial to lateral) infraclavicular incision is made parallel to the long axis of the clavicle so that the scar does not lie over the plate. This approach provides convenient, unlimited access to the entire length of the bone. Option two, an incision along Langer's Lines running perpendicular to the long axis provides better cosmetic results and less damage to the supraclavicular cutaneous nerves.

The lateral platysma is released, and the supraclavicular nerves are identified traversing the anterior aspect of the clavicle and spared. The clavipectoral fascia is then incised along its attachment to the anterior clavicle and carefully elevated in an inferior direction. Dissection is first performed along the medial fragment which is usually flexed up away from the vital intraclavicular structures. In the case of an acute fracture, minimal soft tissue dissection is performed at the fracture site. In cases of nonunion, fibrous tissue is debrided if necessary and the fracture ends drilled to open the intramedullary canal.¹⁸ It is important to keep soft tissue attachments to the butterfly fragments in an attempt to maintain vascularity. The fracture is then reduced.



3 Plate Selection

Select the appropriately sized Locking Anterior Clavicle Plate from the different lengths and curvatures provided. The two middle compression slots may be placed over the fracture, ideally leaving three locking and/or nonlocking holes both proximal and distal to the fracture fragments; however, the plate can be slid medially or laterally for the most ideal location. The curve of the plate can assist in anatomic reduction of the clavicle.

Tips: When an oblique fracture line is present, a lag screw either through the plate or directly into the bone at roughly a 90° angle to the fracture may be used depending upon fracture configuration. Lag screws utilized in this fashion greatly increases the strength of the construct.¹⁹ After the near cortex is drilled with the 3.5mm drill (MS-DC35), the 3.5mm narrow drill guide (PL-2196) is inserted and the far cortex is drilled with a 2.8mm drill (MS-DC28).

Plate benders (PL-2045) are available in the event that plate contouring is required to achieve an exact fit to the clavicle.

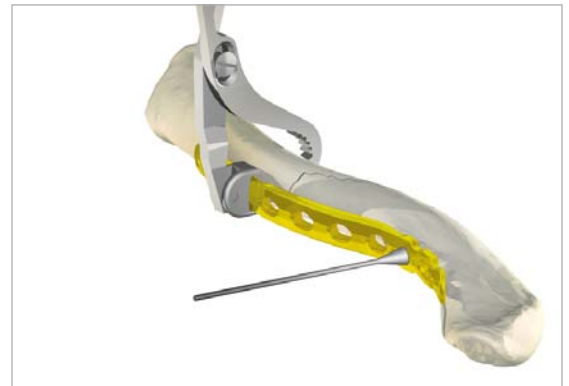


4 Plate Placement

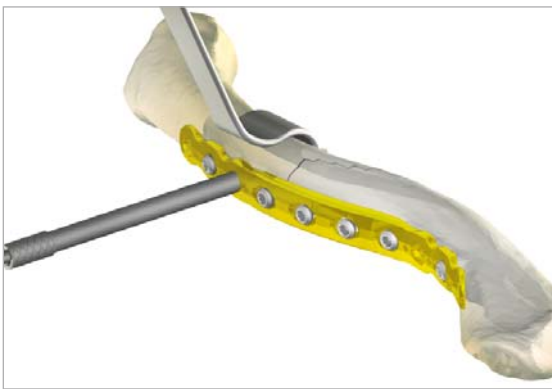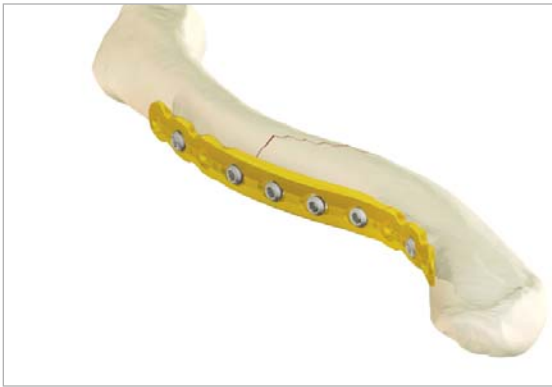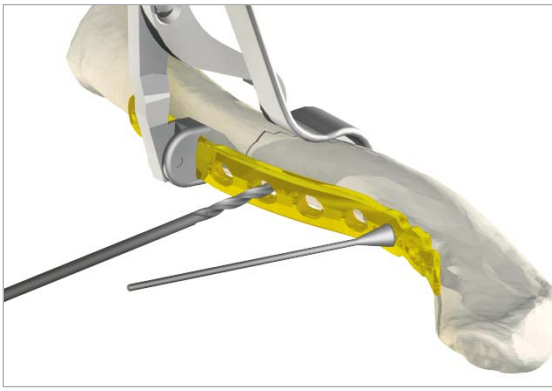Once the plate's ideal positioning has been selected, it is provisionally stabilized to the clavicle with plate tacks (PL-PTACK) or bone clamps (80-0223). The nonlocking screws may be placed either unicortical or bicortical. If bicortical screws are used, it is important not to over-penetrate the posterior cortex and potentially risk neurovascular injury. The clavicle retractor (PL-CL03) is provided as a means of protecting the surrounding neurovascular structures.

Tips: The plate may be rotated 180° for a more anatomical fit.

Avoid using the PL-CL04 plate clamp in securing the plate to the bone as the serrated jaws will cause scarring to the plate surface.



Locking Anterior Clavicle Plate



5 Nonlocking Screw Insertion

Nonlocking screws may be placed either unicortical or bicortical. If bicortical screws are used, it is important not to over-penetrate the posterior cortex and potentially risk injury to the brachial plexus. The clavicle retractor (PL-CL03) or other means of protection should be used to protect from over-penetration of the drill bit. For early stability, the first two screws placed should be medial and lateral to the fracture site. Although 3.5mm cortical screws (CO-3XX0) are recommended, optional 2.7mm cortical (CO-27XX) and 4.0mm cancellous (CA-4XX0) screws are available. Assemble the driver handle (MS-3200) to the driver tip (HPC-0025 or HT-2502). Using the appropriate drill size (MS-DC28) and the offset drill guide (PL-2095), drill, measure for depth (MS-9022) and place the screws into the slots with the assembled driver. Once two screws are installed, the plate tacks or bone clamps holding the plate to the clavicle may be removed.

Tip: Replace drill if it comes into contact with the retractor.

6 Locking Screw Insertion

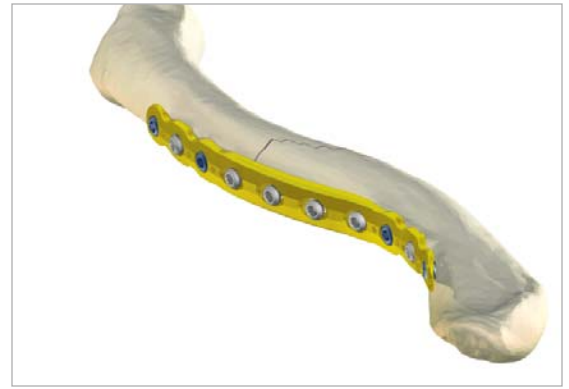Using the locking drill guide (MS-LDG35) and the 2.8mm drill (MS-DC28), place the 3.5mm locking screws (COL-3XX0) into the threaded holes so that there are at least three screws (if possible) on each side of the fracture.

Tips: Tapping (MS-LTT35 or MS-LTT27) is recommended for patients with dense bone. The drill guide must be removed prior to tapping.

Depending on the degree of comminution, demineralized bone matrix, iliac crest autograft, or allograft bone chips may be used to fill areas devoid of bone.²⁰ In hypertrophic nonunions, callus from the nonunion site may be sufficient to provide graft material.

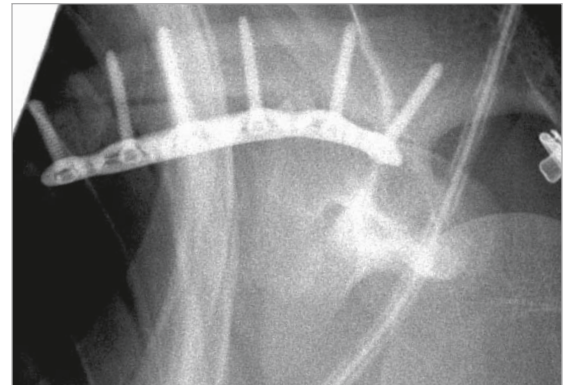7 Final Plate and Screw Position

An intraoperative radiograph is recommended to check the position of the screws and the final reduction of the fracture. If the surgeon feels the bone quality of the lateral fragment is poor, sutures may be passed from medial to lateral around the coracoid and the plate to take stress off of the lateral fixation. After radiographic evaluation and thorough irrigation, the clavipectoral fascia is closed over the clavicle and the plate, followed by closure of the subcutaneous tissue and musculature in separate layers. Finally, close the skin by using interrupted absorbable sutures with a subcuticular stitch and dress the wound.



Post-op Protocol

For the first four weeks, the patient is placed in either an arm sling or an abduction pillow to bring the arm up and the clavicle down, unloading the AC joint.²¹ Passive range of motion exercises are initiated during the first four weeks. Exercises may include pendulum, Codman, isometric bicep, and elbow and wrist motion. It should be emphasized to patients that they must avoid any activity involving heavy lifting, pushing or pulling. Depending on the amount of comminution and the stability of fixation, active assisted exercise is started from four to six weeks, and active strengthening is initiated at six to eight weeks postoperatively, once healing is seen radiographically. Full return to activities is permitted once healing has occurred.

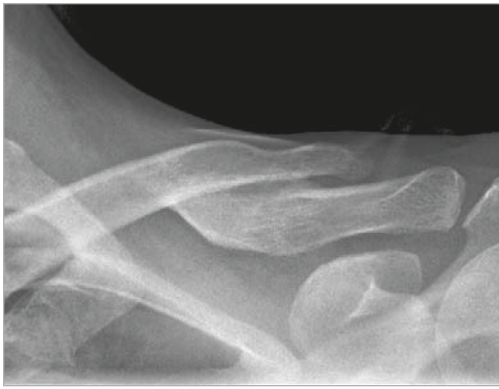

Tip: Due to risk of refracture, implant removal is generally not recommended before two years after ORIF.

Contraindications

Preoperative planning and patient selection are crucial. Patients at high risk for multiple falls, alcohol abuse, or non-compliance may have early mechanical failure of the fixation and are not candidates for this procedure. Additional contraindications include: active infection in the operative area; prior soft tissue irradiation in the operative area; burns over the clavicular area; debilitating medical conditions. Patients who are unable or unwilling to participate in a postoperative rehabilitation program are not candidates for surgical intervention.²²

Locking Distal Clavicle Plate

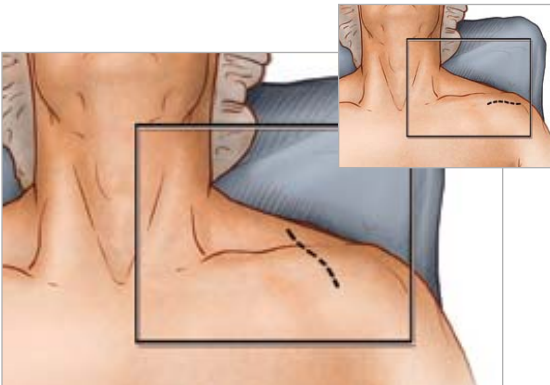


1 Preoperative Planning and Patient Positioning

After a thorough radiographic evaluation has been completed, the patient is placed in a beach chair position with the head rotated and tilted 5° to 10° away from the operative side. A bolster is placed between the shoulder blades allowing the injured shoulder girdle to retract posteriorly. This helps facilitate reduction by bringing the clavicle anterior to restore length and improve exposure. The patient's involved upper extremity is prepped and draped in a sterile fashion allowing the arm to be manipulated to help further reduce the fracture if required.

Tip: After axial trauma to the shoulder, it is important to complete a full clinical workup as this injury is not only a bony injury, but usually a soft tissue event involving the disruption of the coracoclavicular (CC) ligaments and acromioclavicular (AC) joint.²³ Thus, examination of the AC joint and CC ligaments is important in the success of the repair.

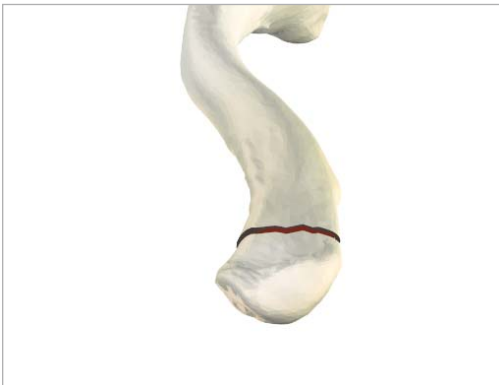Step 1 of the Midshaft and Anterior Clavicle Plate surgical techniques provides a complete profile of options for radiographic evaluation. It is important to note that an AP radiograph can underestimate the displacement of the distal clavicle. If AC joint widening is visualized on the AP view, an axillary radiograph should be taken to determine if an AC separation is present.²⁴



2 Exposure

Surgeons may choose one of two incisions: option one, a 3cm to 5cm transverse incision is made inferior to the distal clavicle and AC Joint. The incision is usually placed midway between the medial/lateral migrations of the proximal fragment. Option two, an incision along Langer's Lines running perpendicular to the long axis provides better cosmetic results and less damage to the supraclavicular cutaneous nerves.

Dissection is carried down to the fascia and the skin flaps are elevated. The cutaneous nerves are protected. The trapezial deltoid musculature is then subperiosteally elevated off the bone fragments avoiding the infraclavicular nerve branches below the clavicle. It is important to keep soft tissue attachments to the butterfly fragments in an attempt to maintain vascularity. The fracture is then reduced.

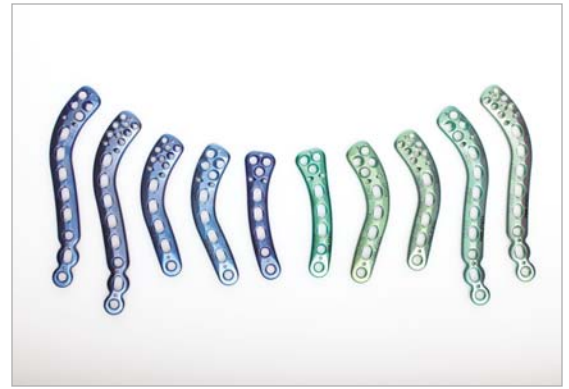


3 Plate Selection

Select the appropriately sized Locking Distal Clavicle Plate from the different lengths and curvatures in the system. The curve of the plate may assist in anatomic reduction of the clavicle, reducing strain on the SC and AC joints.

Tips: Lag screws may be used for interfragmentary fixation. Many Type IIB clavicle fractures have a horizontal cleavage fracture that extends into the AC joint, which may be fixed in this manner.²⁵

Lifting the arm superiorly helps reduce the AC joint. After the near cortex is drilled with the 3.5mm drill (MS-DC35), the 3.5mm narrow drill guide (PL-2196) is inserted and the far cortex is drilled with a 2.8mm drill (MS-DC28). A countersink (PL-2080) is available to facilitate placement of interfragmentary screws.



4 Plate Placement

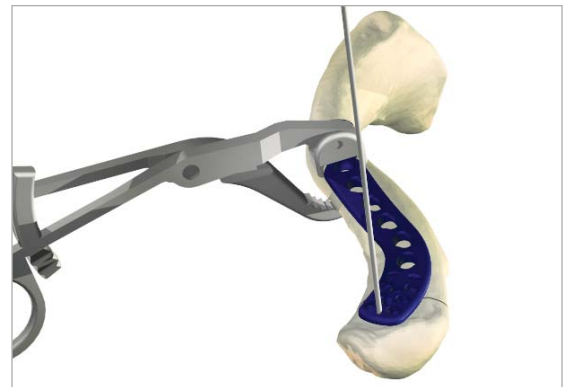
Once the plate's ideal positioning has been selected, it is provisionally stabilized to the clavicle with plate tacks (PL-PTACK) or plate clamps (80-0223). Under radiographic evaluation, the most lateral K-wire hole of each Locking Distal Clavicle Plate affords the opportunity to verify that the placement of the screws will not protrude into the AC joint.

The nonlocking screws may be placed either unicortical or bicortical. If bicortical screws are used, it is important not to over-penetrate the inferior cortex and potentially risk neurovascular injury. The clavicle retractor (PL-CL03) should be placed under the inferior surface to protect the neurovascular structures from over-penetration of the drill bit.

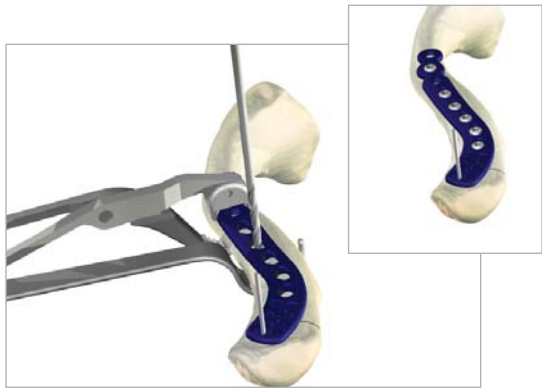
Tips: The plate may be rotated 180° for a more anatomical fit.

Avoid using the PL-CL04 plate clamp in securing the plate to the bone as the serrated jaws will cause scarring to the plate surface.

***Surgical technique from this point forward will highlight a plate utilizing eight 2.3mm screws.**

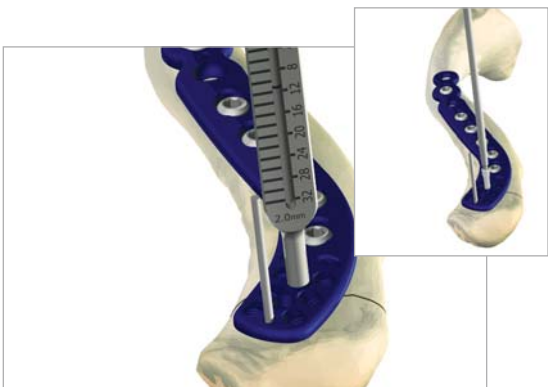


Locking Distal Clavicle Plate



5 Nonlocking Screw Insertion

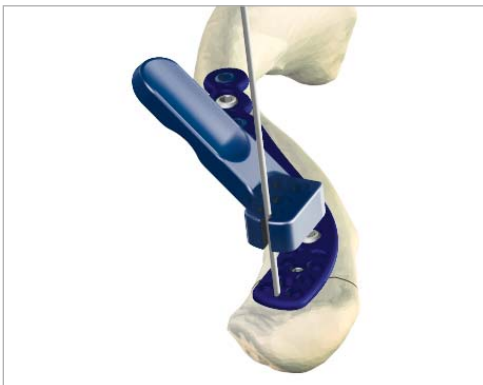For early stability, the first two screws placed should be medial and lateral to the fracture site. Based on the selected plate, 2.3mm non-toggling (CO-N23XX) and 3.5mm cortical screws (CO-3XX0) are recommended (optional 2.7mm cortical screws (CO-27XX) and 4.0mm cancellous (CA-4XX0) screws are available upon request). Assemble the driver handle (MS-3200) to the driver tip (HPC-0025 or HT-2502). Using the appropriate drill size (MS-DC28) and the offset drill guide (PL-2095), drill, measure for depth (MS-9022) and place the screws into the compression slots with the assembled driver. Once the two screws are installed, the plate tacks and bone clamps holding the plate to the clavicle may be removed.



6 Locking Screw Insertion

Before placing the targeting guide (80-0450 / 80-0451) on the plate, secure the plate to a distal fragment by inserting a 2.3mm nonlocking screw through the medial most center hole. To ensure that the plate does not infringe upon the AC joint, place a .059" K-wire (WS-1505ST) through the designated K-wire hole at the far distal end of the plate.

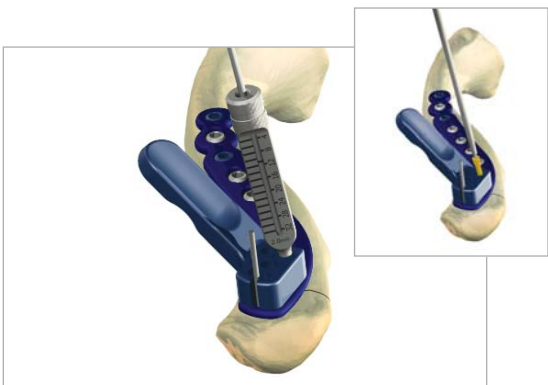
The targeting guides are color coded (blue and green) to match the corresponding left (blue) and right (green) plates. Slide the targeting guide over the K-wire and down to the plate. The correct positioning of the targeting guide is achieved when the two pins on the bottom surface of the targeting guide engage the two suture holes just proximal to the distal screw holes. The targeting guide must sit flush against the plate for proper functionality.



7 Locking Screw Insertion

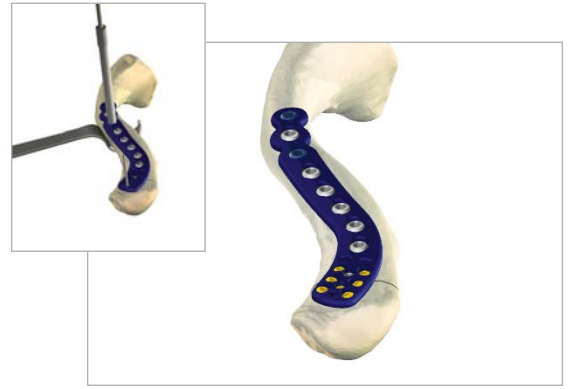For the distal holes, place the 2.0mm Locking Drill Guide (80-0249) into the desired hole and turn clockwise so that the guide fully threads into the plate. This will hold the targeting guide flush to the plate. Insert the 2.0mm drill (80-0318) and advance to the desired depth. Drill depth is determined by referencing where the laser mark on the drill aligns with the measurement on the 2.0mm locking drill guide. When between sizes, choose the shorter screw option. Remove the locking drill guide and insert the proper length of screw through the targeting guide. To place the 2.3mm locking screws (CO-T23XX) into the threaded holes, use the 1.5mm hex driver tip (HPC-0015) with the driver handle (MS-2210). Advance the screw until the screw head fully engages the plate. Repeat these steps until a minimum of six screws have been fully inserted into the plate and bone.

For the shaft portion, use the 3.5mm locking drill guide (MS-LDG35) and the 2.8mm drill (MS-DC28) to place the 3.5mm locking screws (COL-3XX0).



8 Final Plate and Screw Placement

An intraoperative radiograph is recommended to check the position of the screws and the final reduction of the fracture. If the surgeon feels the bone quality of the lateral fragment is poor, sutures may be passed from medial to lateral around the coracoid and through the suture holes in the distal portion of the plate to take stress off of the lateral fixation. After radiographic evaluation and routine irrigation, the trapezial-deltoid fascia is closed over the clavicle and AC joint, followed by closure of the subcutaneous tissue and skin. The wound is dressed and the arm placed in an abduction pillow to bring the arm up and the clavicle down, unloading the AC joint.



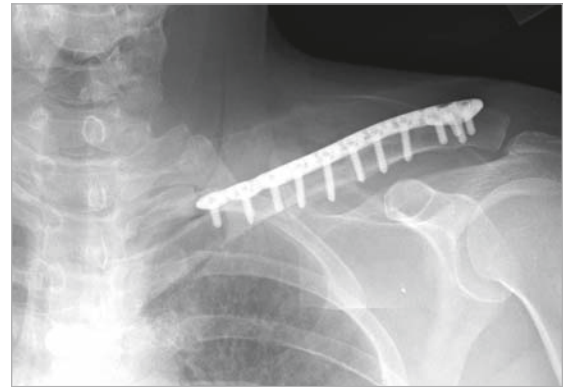
Post-op Protocol

Passive range of motion exercises are initiated during the first four weeks. Exercises may include pendulum, Codman, isometric bicep and elbow and wrist motion. It should be emphasized to patients that they must avoid any activity involving heavy lifting, pushing or pulling. Depending on the amount of comminution and the stability of fixation, active assisted exercise is started from four to six weeks, and active strengthening is initiated at six to eight weeks postoperatively, once healing is seen radiographically. Full return to activities is permitted once healing has occurred.

Tip: Due to risk of refracture, implant removal is generally not recommended before two years after ORIF.

Contraindications

Preoperative planning and patient selection are crucial. Patients at high risk for multiple falls, alcohol abuse, or non-compliance may have early mechanical failure of the fixation and are not candidates for this procedure. Additional contraindications include: active infection in the operative area; prior soft tissue irradiation in the operative area; burns over the clavicular area; debilitating medical conditions. Patients who are unable or unwilling to participate in a postoperative rehabilitation program are not candidates for surgical intervention.²⁶



Additional Shoulder Solutions



Acumed's Locking Scapula Plates are designed to provide excellent fixation for acute fractures, malunions and nonunions of the scapula. Designed in conjunction with William B. Geissler, M.D., Acumed's indication-specific plates allow surgeons to choose a construct based on their patients' needs. The precontoured design eliminates the need to bend the plates to match the patient's anatomy and better restores the functional angle of the shoulder joint. This design not only reduces OR time spent contouring a plate, but also minimizes soft tissue irritation for the patient. The precontoured plates help the surgeon reduce the fracture by acting as templates.



With the Polarus® PHP Locking Proximal Humeral Plate, Acumed has designed an advanced solution for repairing fractures of the proximal humerus. By incorporating a locking construct with an anatomical size and contour that best accommodates the patient, the Polarus® PHP minimizes impingement and soft tissue irritation. To maximize stability in the humeral head, the proximal screws are precisely angled to capture and secure fracture fragments.



The Polarus® Locking Humeral Rod provides excellent fixation for 2, and 3-part fractures of the proximal humerus. This 150mm cannulated intramedullary humeral rod features a tapered profile and patented spiral array of screws that provide multi-planar fixation and serve as a scaffold, restoring the proper anatomic alignment of the humerus through a percutaneous approach.

With lengths offered from 200mm to 280mm, the Polarus® Plus is the perfect solution for fractures of the proximal humerus that extend too far distal for the standard 150mm Locking Polarus® Humeral Rod.



Hemiarthroplasty for proximal humeral fractures is a difficult and demanding surgery. With the Polarus® Modular Shoulder System, both the implant and instrumentation are designed with features to address the common complications of shoulder hemiarthroplasty. Our unique implants feature a humeral head with medial and posterior offset; low-volume grit blasted body; long stems up to 280mm in length and interlocking distal screws. The targeting guide assembly addresses the difficulty of accurate implant positioning by controlling height and retroversion.

Locking Midshaft Clavicle Plate QTY

Low-Profile Clavicle Plate, 8-Hole Straight Left	70-0286	1
Low-Profile Clavicle Plate, 8-Hole Straight Right	70-0287	1
Low-Profile Clavicle Plate, 8-Hole Large Left	70-0288	1
Low-Profile Clavicle Plate, 8-Hole Large Right	70-0289	1
Low-Profile Clavicle Plate, 8-Hole Medium Left	70-0290	1
Low-Profile Clavicle Plate, 8-Hole Medium Right	70-0291	1
Low-Profile Clavicle Plate, 8-Hole Small Left	70-0292	1
Low-Profile Clavicle Plate, 8-Hole Small Right	70-0293	1
Low-Profile Clavicle Plate, 10-Hole Left	70-0294	1
Low-Profile Clavicle Plate, 10-Hole Right	70-0295	1
Narrow-Profile Clavicle Plate, 6-Hole Left	70-0296	1
Narrow-Profile Clavicle Plate, 6-Hole Right	70-0297	1
Narrow-Profile Clavicle Plate, 8-Hole Straight Left	70-0298	1
Narrow-Profile Clavicle Plate, 8-Hole Straight Right	70-0299	1
Narrow-Profile Clavicle Plate, 8-Hole Large Left	70-0300	1
Narrow-Profile Clavicle Plate, 8-Hole Large Right	70-0301	1

Locking Anterior Clavicle Plates QTY

8-Hole Lateral Anterior Clavicle Plate	70-0118	1
8-Hole Medial Anterior Clavicle Plate	70-0119	1
6-Hole Lateral Anterior Clavicle Plate	70-0122	1
6-Hole Medial Anterior Clavicle Plate	70-0120	1
10-Hole Anterior Clavicle Plate	70-0121	1

Locking Distal Clavicle Plates QTY

Distal Clavicle Plate 3.5mm 12-Hole Right	70-0111	1
Distal Clavicle Plate 3.5mm 12-Hole Left	70-0112	1
Distal Clavicle Plate 3.5mm 9-Hole Right	70-0116	1
Distal Clavicle Plate 3.5mm 9-Hole Left	70-0117	1
Distal Clavicle Plate 2.3mm 16-Hole Right	70-0123	1
Distal Clavicle Plate 2.3mm 16-Hole Left	70-0124	1
Distal Clavicle Plate 2.3mm 13-Hole Right	70-0125	1
Distal Clavicle Plate 2.3mm 13-Hole Left	70-0126	1
Low-Profile Clavicle J-Plate, 8-Hole Left	70-0319	1
Low Profile Clavicle J-Plate, 8-Hole Right	70-0320	1

Universal Tray and Screw Caddies QTY

Universal Tray Large Assembly	80-0341	1
Universal Tray Screw Insert Assembly	80-0395	1
Universal Tray 2.7mm Sub-caddy	80-0350	1
Universal Tray 3.5 mm Sub-caddy	80-0351	1
Universal Tray 4.0 mm Sub-caddy	80-0352	1

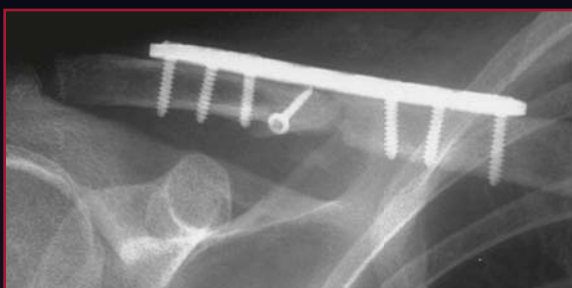
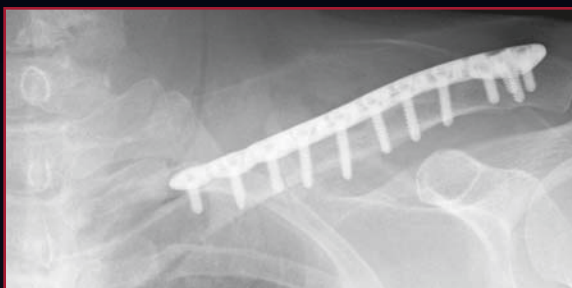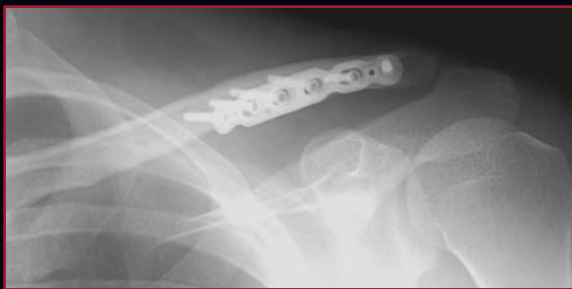Locking Distal Clavicle Instrumentation QTY

Locking Clavicle 2 Insert Assembly	80-0307	1
Cruciform Driver Handle	MS-2210	1
1.5mm Hex Driver Tip (small shaft)	HPC-0015	2
2.3mm Screw Sleeve	MS-SS23	1
2.0mm Locking Drill Guide 4mm-32mm	80-0249	2
2.0mm Quick Coupler Surgibit Drill	80-0318	2
Targeting Guide, Distal Clavicle Plate, Right	80-0450	1
Targeting Guide, Distal Clavicle Plate, Left	80-0451	1
.035" Depth Probe	80-0357	1

Locking Midshaft Clavicle Instrumentation QTY

Universal Tray Low-Profile Clavicle Insert Base	80-0525	1
Universal Tray Low-Profile Clavicle Insert Lid	80-0526	1
2.5mm Flexible Hex Driver	80-0302	1
2.5mm Solid, Quick Release, Driver Tip	HT-2502	1
Clavicle Retractor	PL-CL03	1
Countersink	PL-2080	1
3.5mm Tap Sleeve Assembly	PL-2190	1
Sharp Hook	PL-CL06	1
2.8mm / 3.5mm Lag Guide	MS-DS2835	1

These implants are available nonsterile or sterile-packed. Add -S to product number for sterile products. To order, contact your local Acumed Representative.



REFERENCES

1. Bostman et al, *Journal of Trauma: Injury, Infection, and Critical care*. 1997; 5: 778-783.
2. Iannotti et al, *Journal of Shoulder and Elbow Surgery*. 2002 September / October; 11 (5): 457-462.
3. Daruwalla, Z., *Geometric Morphology of the Clavicle and It's Clinical Relevance, Including Fixation Device Design Based on Statistical Shape and Principal Component Analyses*.(Thesis, Royal College of Surgeons in Ireland, October 2009).
4. Xiao, L. et al, *The Distal Clavicle Morphology*. *Techniques in Shoulder & elbow Surgery* 9(2): 80-84, 2008.
5. Data on file at Acumed.
6. Goswami et al, *Biomechanical evaluation of a pre-contoured clavicle plate*. *Journal of Shoulder and Elbow Surgery*. 2008 September/October; 17 (5): 815-818.
7. Goswami et al
8. Data on file at Acumed.
9. Luo, CF., *Locking compression plating: a new solution for fractures in rheumatoid patients*. *Modern Rheumatology* 2005; 15: 169-172.
10. Data on file at Acumed.
11. Bishai, S., Plancher, K., Areson, D. *Operative Treatment for Comminuted Midshaft Fractures and Type II Distal Clavicle Fractures With Plating Techniques*. *Fractures of the Upper Extremity*. American Society for Surgery of the Hand. 2008.
12. Renner et al, *Scapula and Clavicle*. *AO Principles of Fracture Management*. AO Publishing (Theime). 2007. 557-571.
13. Bishai et al.
14. Bishai et al.
15. Altamimi, S., McKee, M. *Nonoperative Treatment Compared with Plate Fixation of Displaced Midshaft Clavicular Fractures (Surgical Technique)* *Journal of Bone and Joint Surgery*. 2008; 90 Supplement (part1): 1-8
16. Bishai et al.
17. Collinge et al, *Anterior-inferior Plate Fixation of Middle-third Fractures and Nonunions of the Clavicle*. *Journal of Orthopaedic Trauma*. November/ December 2006; 20 (10): 680-686.
18. Collinge et al
19. Bishai et al.
20. Bishai et al.
21. Bishai et al.
22. Altamimi et al.
23. Yeh, et al, *Midshaft clavicle fracture and acromioclavicular dislocation: A case report of a rare injury*. *Journal of Shoulder and Elbow Surgery*. 2008 December; Article in Press :1-4.
24. Yeh et al.
25. Bishai et al.
26. Altamimi et al.

ACUMED[®]

5885 NW Cornelius Pass Road

Hillsboro, OR 97124

(888) 627-9957

www.acumed.net

Distributed by:

These materials contain information about products that may or may not be available in any particular country or may be available under different trademarks in different countries. The products may be approved or cleared by governmental regulatory organizations for sale or use with different indications or restrictions in different countries. Products may not be approved for use in all countries. Nothing contained on these materials should be construed as a promotion or solicitation for any product or for the use of any product in a particular way which is not authorized under the laws and regulations of the country where the reader is located. Specific questions physicians may have about the availability and use of the products described on these materials should be directed to their particular local sales representative. Specific questions patients may have about the use of the products described in these materials or the appropriateness for their own conditions should be directed to their own physician.

SHD00-00-C

Effective: 2/2010